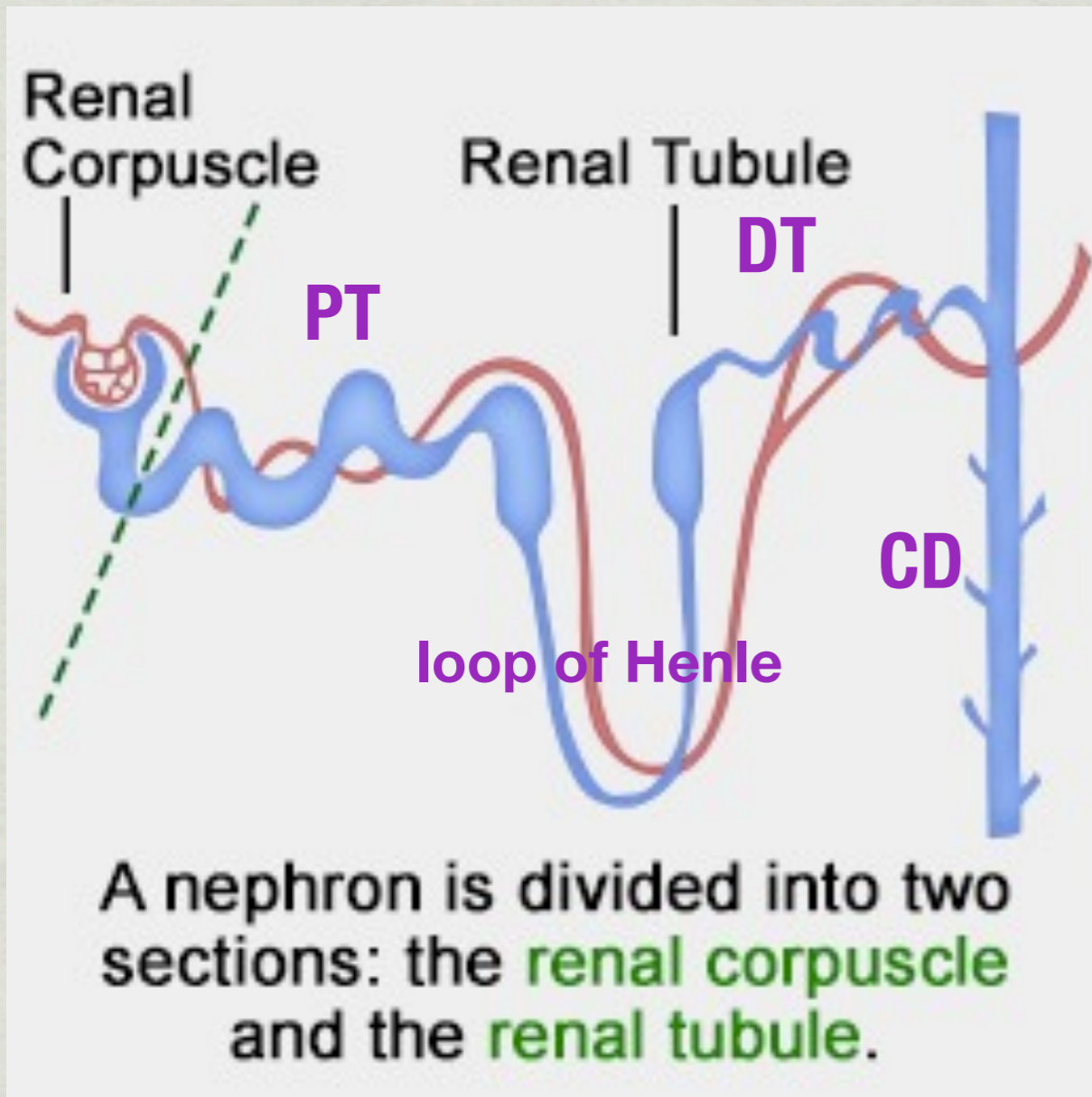


# Nephron anatomy



- \* **Renal corpuscle:**
  - Bowman capsule
  - glomerulus
- \* **Renal tubule:**
  - proximal **PT**
  - **loop of Henle** with 2 limbs: thin and thick ascending
  - distal **DT**
  - collecting duct **CD**