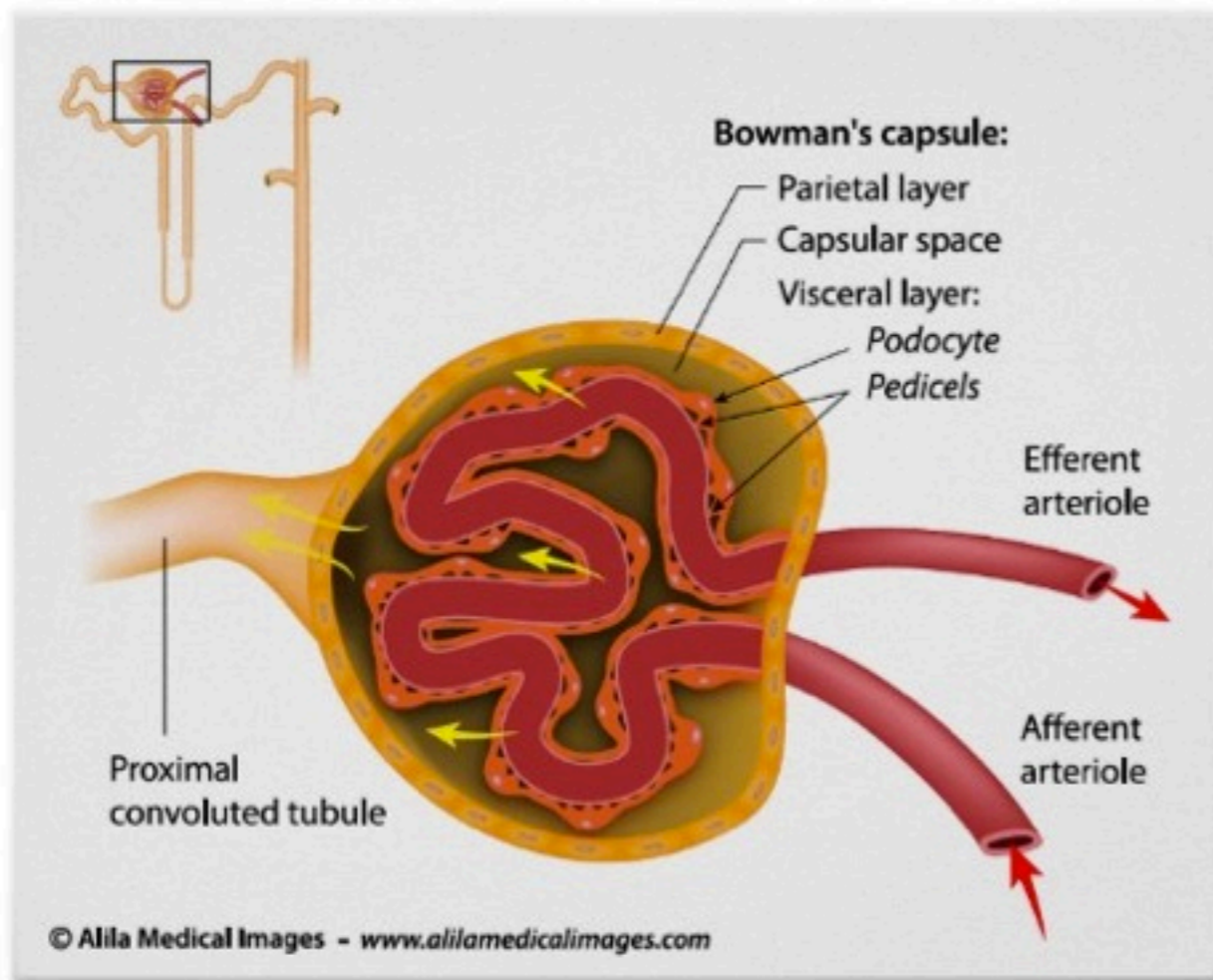


# Renal corpuscle anatomy



Bowman's capsule:

1, 2 and 3

1. Parietal layer

epithelial cells  
continue on PT

2. Capsular space

btw 1 and 3

3. Visceral layer  
(podocytes)

epithelial cells with  
foot processes  
(pedicels)

Glomerulus

endothelial capillary  
fenestrated cells

Arterioles aff. & eff.

in & out capsule

Renin releasing  
(JG cells)

modified muscular  
cells on aff. art.

Macula densa

cells on DT  
sensitive to Na  
conc.