
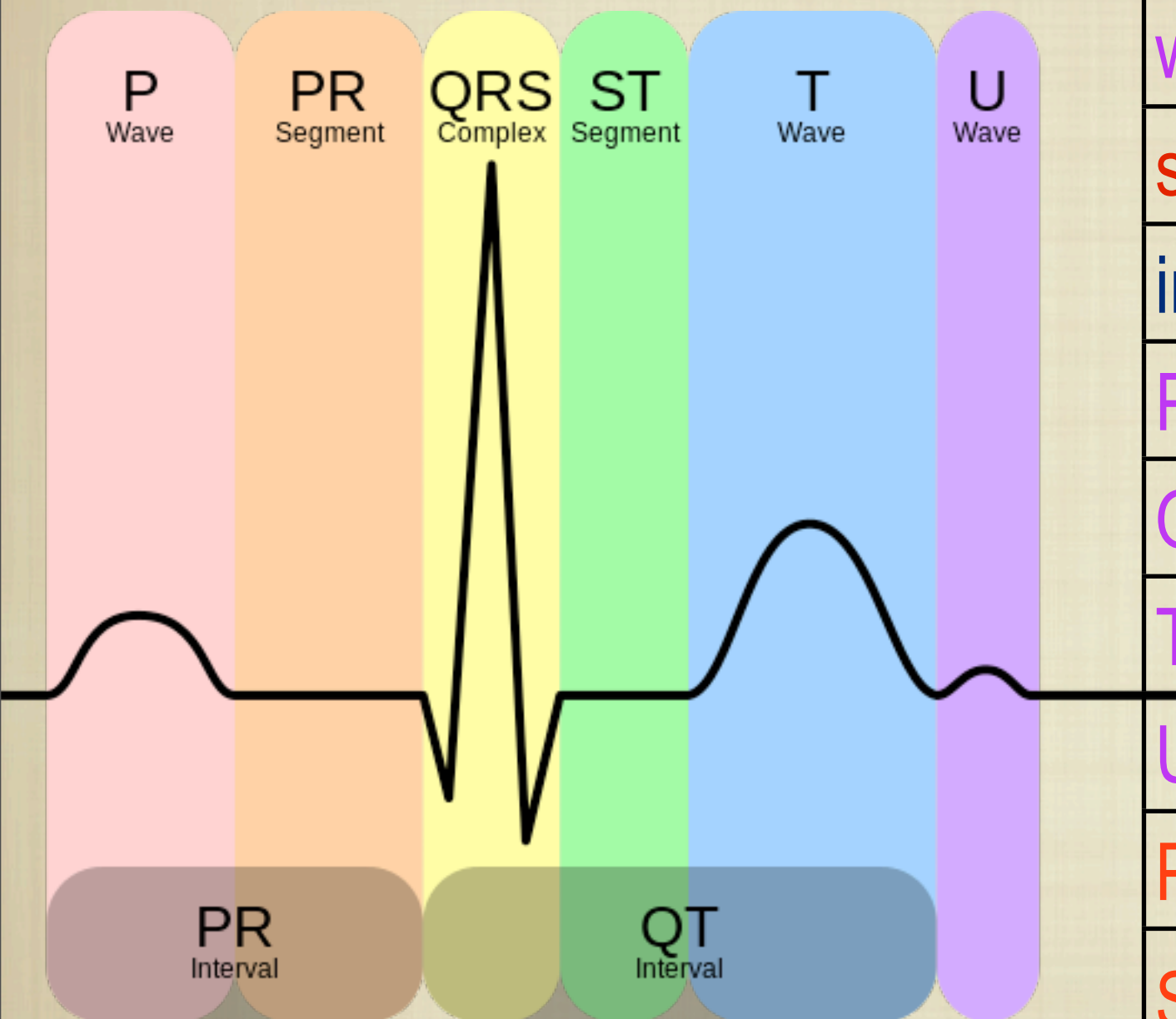


# EKG: COMPONENTS & DESCRIPTION



Ask Mish



wave	deflection up/down
segments	horizontal lines btw waves
interval	wave(s) + segment(s)
P wave	atrial depolarization
QRS complex	ventricular depolarization
T wave	ventricular repolarization
U wave	not known; after repolarization
PR segment	short AP block at AV node
ST segment	time btw ventricular depol. and repolarization