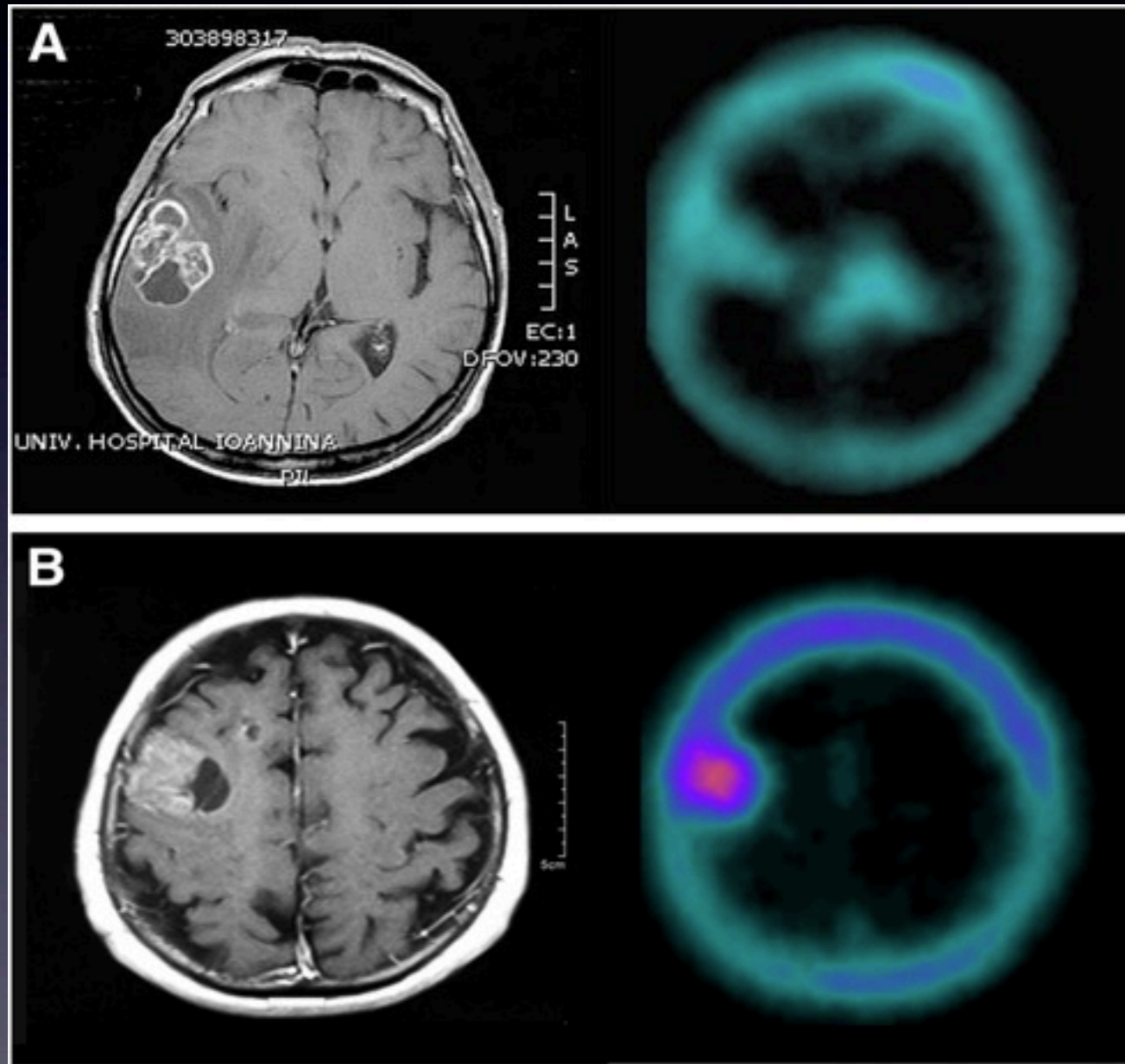




Ask Mish

# Brain SPECT scan example



**The Value of 99mTc-Tetrofosmin Brain SPECT in Predicting Survival in Patients with Glioblastoma Multiforme**

Contrast-enhanced T1-weighted MR image (left) and 99mTc-tetrofosmin SPECT image (right) in one GBM patient exhibiting low tracer uptake (A) and in another with high uptake (B).