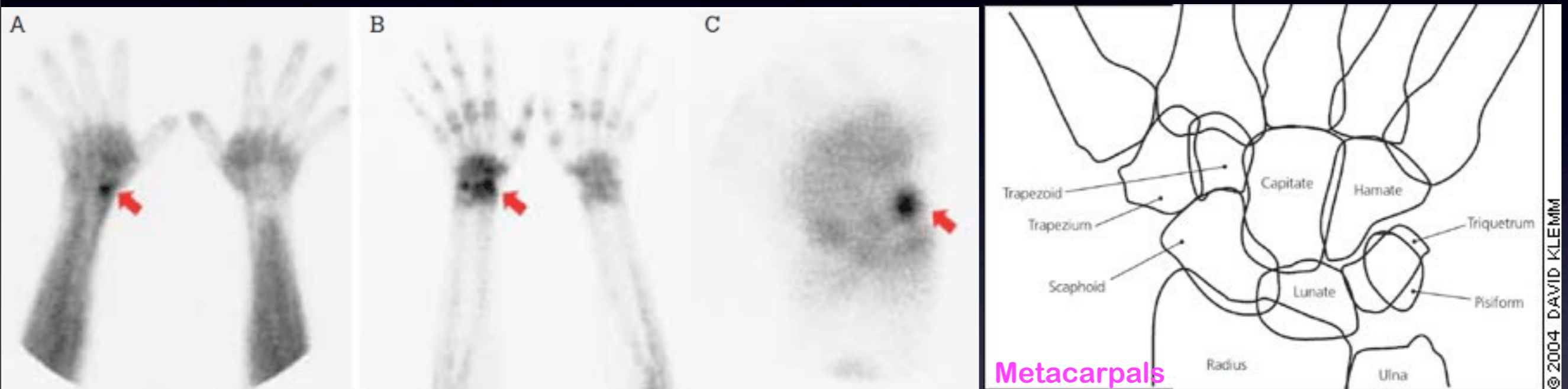


Bone scan example: scaphoid fracture



Ask Mish



A man, 28 years of age, had persistent pain in the right anatomical snuffbox following a fall onto his outstretched right hand. X-ray was normal, prompting referral for a bone scan. It demonstrated focally increased radiotracer accumulation in the scaphoid on both blood pool (A) and delayed images (B), typical of a scaphoid fracture. C is magnified delayed image.